

# Chronic Exertional Compartment Syndrome: More than Shin Splints



“(My trainers and doctors) tried to take me out of gymnastics completely, where they only wanted me to compete at meets, they didn’t want me practicing at all. So, obviously, I said no to that. I went into a very dark place for a few weeks until we came to a compromise that I could still do my sport, but it was super hard to comprehend that they wanted me to be done.”

## CASE HISTORY

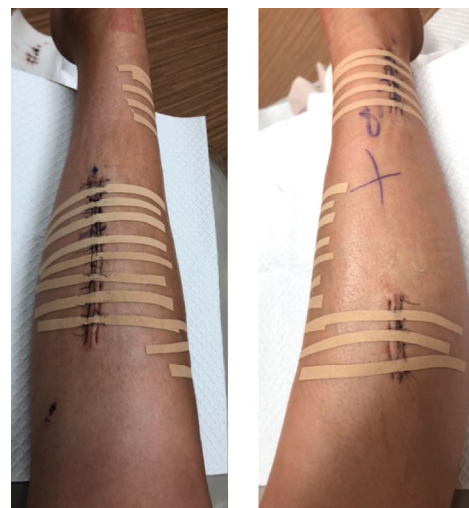

State champion, female high school gymnast, Lacey Scheid was diagnosed with Chronic Exertional Compartment Syndrome (CECS). For months, her trainer and doctors treated her condition as shin splints, reducing her training and recommending that she wear a walking boot. The delayed diagnosis resulted in lost training and competition time and additional stress.

## DIAGNOSIS

The patient’s high school trainers initially diagnosed Lacey’s condition as shin splints and recommended rest and ice. As time went on, her condition worsened so her trainers referred her to physicians for further testing. An X-Ray and MRI were ordered to rule out a stress fracture. Both tests came back with normal findings. For precautionary reasons, Lacey remained in a walking boot for three weeks until the physicians ordered testing for Chronic Exertional Compartment Syndrome (CECS). Diagnosis included testing the patient’s compartment pressure at rest as well as following exercise on a treadmill utilizing an intra-compartmental pressure monitor. Results showed elevated pressures in all four compartments of the patient’s right leg. One year later, she was also diagnosed with chronic exertional compartment syndrome in her left leg.

## TREATMENT MODALITY

After the compartment pressure testing confirmed a CECS diagnosis, the patient underwent a fasciotomy on her right leg followed by several months of physical therapy. She continues to experience minor nerve damage and sensation which is dissipating over time. Six months after her initial fasciotomy, the patient began to experience similar symptoms in her left leg and underwent pressure testing to confirm a CECS diagnosis. In the summer of 2022, she had another fasciotomy followed by additional physical therapy.



“It’s nice not being in pain, and I can’t wait for next season when I’m completely out of pain.”  
– Lacey Scheid



**PROGNOSIS**

Following months of pain, symptoms, and a delayed CECS diagnosis, the patient continues to experience loss of sensation in her right foot in addition to a subsequent CECS diagnosis in her left leg. The patient is undergoing another round of physical therapy with hopes to be able to compete during her senior gymnastics season.

**IMPLICATIONS FOR CLINICIANS**

Persistent and recurrent symptoms of leg pain, cramping, and tightness in any athlete warrants consideration of CECS. To help prevent delayed or missed diagnosis, education and awareness of compartment syndrome should be a priority for orthopedic, sports medicine, athletic training, and physical therapy practitioners.

Early suspicion and testing with the STIC Pressure Monitor, previously from Stryker and now available through C2Dx, can aid in an early CECS diagnosis.

**Diagnostic Differentiators**

	<b>CECS</b>	<b>SHIN SPLINTS</b>
<b>Location of Pain</b>	Pressure/pain is often experienced on the outside front of the lower leg.	Pain is generally on the inside front of the lower leg, or the outside of the upper leg.
<b>Nerve-Related Symptoms</b>	Numbness and/or tingling on the top of the foot.	No symptoms related to nerves.
<b>Diagnostic Process</b>	Intra-compartmental pressure measurements using a pressure monitor is the only definitive, data-based clinical diagnosis.	In some cases, an X-ray or other imaging studies can help identify stress fractures associated with shin splints.

