

# Nare Obstruction Due to Massive Rhinophyma Treated Using the Shaw Scalpel

E. VINNY SEIVERLING, MD, AND ISAAC M. NEUHAUS, MD\*

---

*The authors have indicated no significant interest with commercial supporters.*

---

Rhinophyma is a subtype of rosacea characterized by nodular thickening of the skin, sebaceous gland hyperplasia, dilated pores, and in its late stage, fibrosis. Phymatous changes in rosacea are most common on the nose but can also occur on the chin (gnatophyma), ears (otophyma), and eyelids (blepharophyma).<sup>1,2</sup> In severe cases, phymatous changes result in the loss of normal facial contours, significant disfigurement, and social isolation. Additionally, patients with profound rhinophyma can experience nare obstruction and difficulty breathing due to the weight and bulk of their nose.<sup>3</sup> Treatment options for severe advanced rhinophyma include cryosurgery, partial-thickness decortication with subsequent secondary reepithelialization, carbon dioxide (CO<sub>2</sub>) or erbium-doped yttrium aluminum garnet (Er:YAG) laser ablation, full-thickness resection with graft or flap reconstruction, excision by electrocautery or radio frequency, and sculpting resection using a heated Shaw scalpel.<sup>4</sup> We report a severe case of rhinophyma resulting in marked facial disfigurement and nasal obstruction treated successfully using the Shaw scalpel. Rhinophymectomy using the Shaw scalpel allows for efficient and efficacious treatment of rhinophyma without the need for multiple procedures or general anesthesia and thus should be considered in patients with nare obstruction who require intervention.

## Case Report

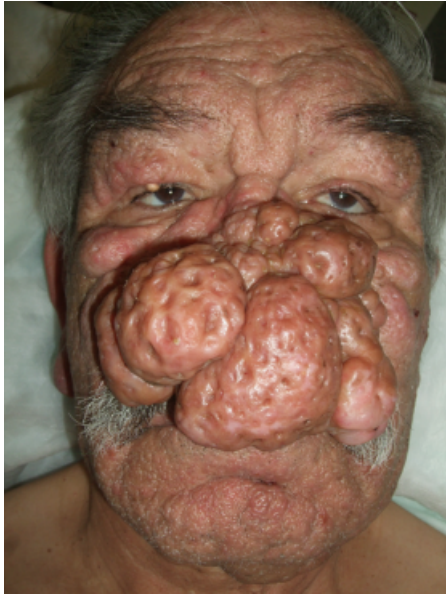
A 65-year-old man presented with a 20-year history of progressive enlargement of his nose. The patient

had a history of cystic acne as a teenager and was diagnosed with rosacea in his 30s. Over the subsequent years, his nose had slowly enlarged and lost its normal contour. He had difficulty breathing at night and poor sleep due to nare obstruction. To maintain airway patency he placed plastic cannulae inside his nares. In addition to breathing difficulty, the massive nasal distortion caused him to limit his social interactions because of concern about disfigurement. His only prior treatment for rosacea was doxycycline, but he had not been taking any medications or using any topical agents for the past 5 years. Treatment with retinoids had never been attempted, and he had not undergone any laser or surgical interventions. The patient had no other medical problems but reported previous heavy alcohol intake. There was no family history of rosacea. The review of systems was positive for the aforementioned breathing difficulties and emotional distress but negative for ocular symptoms and flushing.

Physical examination revealed pustules and nodulocystic areas on the forehead, cheeks, and temples. The nose was composed of exophytic lobular papules and nodules forming a 14- × 19-cm exophytic bulbous mass resulting in complete obliteration of the normal nasal contour. Large dilated pores and areas of crusting were also present. In addition, there was lobular expansion of the bilateral earlobes and chin (Figure 1).

A shave biopsy taken from the nose confirmed the clinical diagnosis of rhinophyma and excluded a

\*Both authors are affiliated with Department of Dermatology, University of California at San Francisco, San Francisco, California

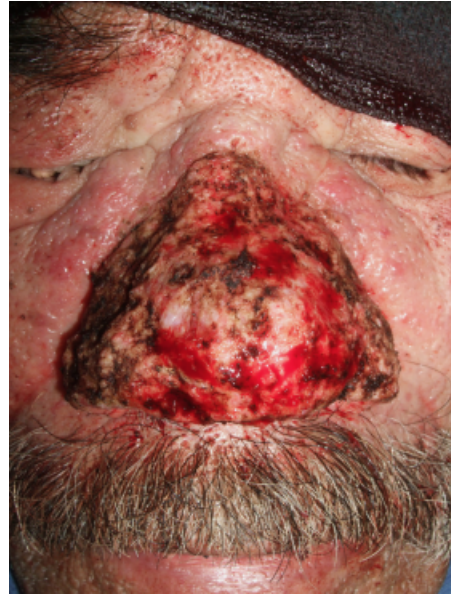

**Figure 1.** Massive rhinophyma.

granulomatous infectious process. Tissue culture was negative for acid-fast bacilli and other bacteria. A magnetic resonance imaging scan showed no bony abnormalities of the face and patent sinuses.

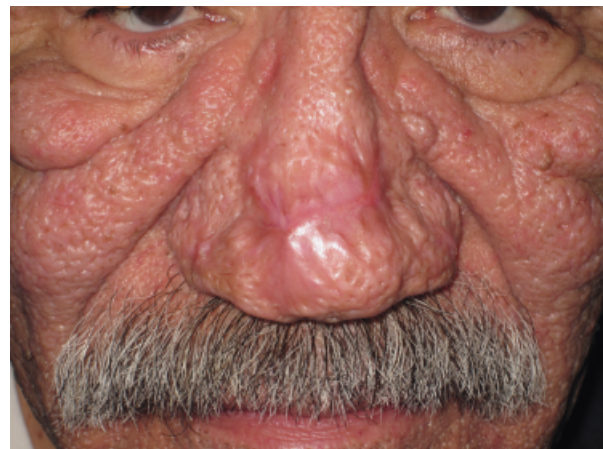Various treatment options were discussed with the patient. After extensive discussion of the techniques, risks, benefits, and alternatives of different interventions, rhinophymectomy using the Shaw scalpel was undertaken.

The procedure performed was similar to one that Eisen and colleagues described.<sup>3</sup> The anterior ethmoidal nerve was blocked bilaterally with 1% lidocaine with 1:1,00,000 epinephrine. Additional anesthesia was achieved using a ring block around the entire nose. A Shaw scalpel with a #10 blade was set to a temperature of 160°C and used to debulk hyperplastic tissue and contour the nose to the desired shape (Figure 2). Old photos of the patients were used as a guide to establish his baseline nasal contour. Gauze soaked in 1% lidocaine with 1:1,00,000 epinephrine was used topically for further hemostasis before dressing application. A pressure dressing to the entire nose was left in place for 2 days.



**Figure 2.** Immediately following rhinophymectomy with Shaw scalpel.

The patient tolerated the procedure well and was closely followed during the postoperative period for dressing changes. The skin reepithelialized completely over the ensuing several weeks. At a 4-month follow-up visit, a scar was present on the nasal dorsum, but the overall nasal contour was restored and his nares were patent (Figure 3). The patient was extremely happy with the final outcome. He repeatedly stated that he no longer avoided social interactions and would go out of his way to be in



**Figure 3.** 8 months post-op.

public places. In addition, his breathing difficulties had resolved, and he no longer had trouble sleeping.

## Discussion

Treatment of advanced rhinophyma can be challenging. A variety of surgical interventions have been attempted with good results. Sculpting resection and recontouring using the Shaw scalpel was performed in this case because of its efficiency, efficacy, precision, and excellent hemostasis as a single modality under local anesthesia. Given the amount of hyperplastic tissue in this patient, using the Shaw scalpel for rhinophymectomy proved to be an efficient modality to debulk the nose. Effective treatment with a single intervention is indicated when respiratory compromise (nasal airway obstruction or difficulty eating) is present. Additionally, the Shaw scalpel is easily portable and is a much more cost-effective outpatient procedure than other surgical options. Despite this being “older technology,” recent reports demonstrate that many surgeons still use it and that it should thus be considered an appropriate treatment option for rhinophyma.<sup>5</sup>

Cold steel removal of hyperplastic tissue, with resulting reepithelialization from the remaining pilosebaceous units, can achieve excellent outcomes, although suboptimal hemostasis with this modality can result in poor visualization and inaccurate sculpting. Dermabrasion can provide fine control for smoothing nasal contour, but intraoperative bleeding is often problematic. Ablative laser surgery, using the CO<sub>2</sub> or Er:YAG laser, is an excellent treatment option for rhinophymectomy. Laser allows for precise intraoperative destruction and hemostasis,<sup>6,7</sup> although significant risk of scarring and dyspigmentation remains, as well as the extensive operating time required for the treatment of severe cases of rhinophyma such as in this case. Electro-surgery is a relatively quick technique that achieves a bloodless field similar to the Shaw scalpel, but the current produced within the tissue can result in a less-precise zone of tissue destruction and thus car-

ries a higher risk of scarring.<sup>8</sup> Cryosurgery using multiple treatment sessions has been described as an option for rhinophyma. Disadvantages with this modality include the need for multiple visits, scarring and dyspigmentation, and lack of depth and contour control.<sup>9</sup> Lastly, although full-thickness resection and reconstruction with a graft or flap allows for treatment in a single intervention, it requires general anesthesia and creates a wound at the donor site, and the donor skin may not match the facial skin in color and texture.<sup>10</sup>

Our patient had immediate improvement in his breathing and overall quality of life. He was extremely pleased with the final cosmetic outcome, despite the presence of scarring on the nose. It is possible that staged treatments or less-aggressive contouring would have decreased the likelihood of this, but scarring and dyspigmentation can occur with any ablative or surgical treatments for rhinophyma.<sup>4,5</sup> Regardless of the treatment modality, a complete discussion of the risks, benefits, and alternatives should take place before any procedure.

This case of extensive, disfiguring rhinophyma with airway obstruction was successfully treated using sculpting resection and recontouring using the Shaw scalpel. The procedure was performed on an out-patient basis without general anesthesia, blood loss was minimal, and the patient was rapidly relieved of his breathing difficulty. His overall quality of life and ability to interact socially without hesitation was restored.

## References

1. Crawford GH, Pelle MT, James WD. Rosacea: I. Etiology, pathogenesis, and subtype classification. *J Am Acad Dermatol* 2004;51:327–4.
2. Ezra N, Greco JF, Haley JC, Chiu MW. Gnatophyma and otophyma. *J Cutan Med Surg* 2009;13:266–72.
3. Eisen RF, Katz AE, Bohigian RK, Grande DJ. Surgical treatment of rhinophyma with the Shaw scalpel. *Arch Dermatol* 1986;122:307–9.
4. Pelle MT, Crawford GH, James WD. Rosacea II. Therapy. *J Am Acad Dermatol* 2004;51:499–512.

5. Vural E, Royer MC, Kokoska MS. Sculpting resection of rhinophyma using the Shaw scalpel. *Arch Facial Plast Surg* 2009;11:263–6.
6. Madan V, Ferguson JE, August PJ. Carbon dioxide laser treatment of rhinophyma: a review of 124 patients. *Br J Dermatol* 2009;161:814–8.
7. Fincher EF, Gladstone HB. Use of dual-mode erbium:YAG laser for the surgical correction of rhinophyma. *Arch Facial Plast Surg* 2004;6:267–71.
8. Aferzon M, Millman B. Excision of rhinophyma with high-frequency electrosurgery. *Dermatol Surg* 2002;28:735–8.
9. Kempiak SJ, Lee PW, Pelle MT. Rhinophyma treated with cryosurgery. *Dermatol Surg* 2009;35:543–5.
10. Akhdari N, Ettalbi S, Rachid M, Amal S. Rhinophyma: a giant presentation. *Clin Exp Dermatol* 2009;34:536–7.

---

Address correspondence and reprint requests to: Isaac M. Neuhaus, MD, 1701 Divisadero Street, 3rd Floor, San Francisco, CA 94115, or e-mail: neuhausi@derm.ucsf.edu

Copyright of Dermatologic Surgery is the property of Wiley-Blackwell and its content may not be copied or emailed to multiple sites or posted to a listserv without the copyright holder's express written permission. However, users may print, download, or email articles for individual use.