

## Endoscopic sialolith removal: orientation and shape as predictors of success

Rohan R. Walvekar, MD, Ricardo L. Carrau, MD, Barry Schaitkin, MD\*

*Department of Otolaryngology and Head and Neck Surgery, University of Pittsburgh Medical Center, Pittsburgh, PA*

Received 4 February 2008

### Abstract

**Purpose:** To identify factors that may influence successful retrieval of salivary stones with interventional sialendoscopy.

**Materials and methods:** A retrospective chart review of sialendoscopy procedures performed in the Department of Otolaryngology at the University of Pittsburgh from July 2005 to August 2007 was conducted. We identified thirty consecutive cases of sialolithiasis treated with sialendoscopy.

**Results:** The mean age at presentation was 45 years (range, 7–77 years) with a male-to-female sex ratio of 1:1.5. The most common presentation was recurrent or persistent salivary gland swelling (53%), followed by salivary gland swelling associated with meals (37%). All these procedures were performed under sedation or general anesthesia. Size of the stones ranged from 0.2 to 1.2 cm. Our success rate for their endoscopic removal was 74% (14/19). Four patients (4/30) required a planned combined technique for stone removal.

**Conclusions:** Sialendoscopy is a reasonable minimally invasive option to treat sialolithiasis that avoids the need for salivary gland excision. Salivary stones larger than 4 mm for submandibular cases and 3 mm for parotid cases may be amenable to endoscopic removal provided their largest dimension is orientated favorably along the length of the duct.

© 2009 Elsevier Inc. All rights reserved.

### 1. Introduction

Sialendoscopy is an effective minimally invasive approach to diagnose and treat obstructive disorders affecting the ductal system major salivary glands such as sialolithiasis. This procedure allows the safe extraction of salivary ductal stones obviating the need to excise the gland. As a result, risks associated with traditional surgical procedures for the submandibular and parotid gland such as injury of the marginal mandibular, lingual or facial nerves, as well as damage to the hypoglossal and local sensory nerves are eliminated. However, sialendoscopy is associated with certain limitations. Usually, endoscopic removal of a sialolith using a wire basket is limited to submandibular gland stones with a diameter of less than 4 mm and parotid gland stones with a maximum diameter of less than 3 mm

[1]. Removal of larger stones require either prior fragmentation using alternative techniques such as laser or lithotripsy, or a combined technique incorporating endoscopy and an open surgical procedure [1,2]. In the United States, prior fragmentation using laser or external lithotripsy has not been approved by the Food and Drug Administration. As a result, the diameter of the stone becomes a limiting factor for their endoscopic removal. From our observations, however, we propose that, in addition to the largest diameter, the shape and orientation are equally important factors that can predict successful endoscopic sialolith removal [1] and must be incorporated into the algorithm for clinical decision making.

### 2. Materials and methods

We completed a retrospective review of all cases of sialendoscopy performed in the Department of Otolaryngology–Head & Neck Surgery at the University of Pittsburgh Medical Center from July 2005 to August 2007. We obtained

\* Corresponding author. Department of Otolaryngology and Head Neck Surgery, University of Pittsburgh, Pittsburgh, PA 15213, USA. Tel.: +1 412 647 2100; fax: +1 412 647 2080.

Table 1  
Size of the stone: endoscopic approach and combined technique

	Removal successful	Removal failure
SMG	2–9 mm	4–12 mm
Parotid	2–7 mm	2*–7 mm

\* In this particular case, the Stenson's duct was inflamed and the scope could not be passed successfully.

Table 2  
Endoscopic approach: distribution of stone and outcomes

		SMG	Parotid	
Successful retrieval	74% (14/19)	9	5	14
Nonretrieval (12)	Stone size	3	2	5
	Other factors	4	3	7

approval from the institutional review board before embarking on this study. Demographic and clinical data were collected including age, sex, surgical indications, preoperative imaging, operative time, type of procedure (endoscopic or combined intervention), as well as associated complications and their management (being reported as a separate study). Dimension and number of sialoliths and other relevant preoperative imaging findings were documented.

All the procedures were performed using a 1.3-mm Marchal sialendoscope (Karl Storz, Tuttlingen, Germany) [1]. For purely endoscopic cases requiring a papillotomy, marsupialization of the ductal opening was not performed in a standardized manner. In most cases, delivering the stone from the duct required incision of the punctum; therefore, it was not recorded as a separate procedure.

We obtained a preoperative consent for a combined approach in cases in which we anticipated difficulties with the endoscopic stone retrieval. In the combined technique, endoscopic visualization and localization of the stone was followed by a standard external or intraoral approach to remove the stone avoiding removal of the involved gland. This was followed by repair of the duct with placement of a stent or, alternatively, marsupialization of the duct.

### 3. Results

All procedures were performed endoscopically. In addition, in 4 patients, a combined intervention (endoscopy with open surgical approach) was necessary. The procedure was performed on the submandibular gland in 67% (19/30), parotid gland in 37% (11/30), and on both salivary glands in 3 cases. The most common presentation was recurrent or persistent salivary gland swelling (53%), followed by salivary gland swelling associated with meals (37%). Three patients (10%) presented with recurrent sialadenitis.

#### 3.1. Sialolithiasis

The size of the stones ranged from 2 to 12 mm, (Table 1). The results of endoscopic stone removal are described in Table 2. The overall success rate for an endoscopic for stone removal was 74% (14/19). The average size of the stones removed via endoscopic approach using a wire basket from the submandibular gland and parotid gland was 4.5 and 4.4 mm, respectively. In this series, the largest dimension for stones that were removed endoscopically was 9 mm for submandibular and 7 mm for parotid stones, respectively. The results of stone removal for large stones (>5 mm) is listed in Table 3. For stones with diameter of less than 4 mm for the submandibular gland and less than 3 mm for parotid gland, the success rates for endoscopic removal was 67% (4/6) and 100% (3/3), respectively. Of the 12 cases of failed stone retrieval via an endoscopic approach, failure was related to the size of the stone in 42% (5/12), inability to navigate the scope to the stone in 50% (6/12) cases, and 1 case of a retained stone in the submandibular duct remnant after submandibular gland excision (8%). This stone was later passed through a fistulous tract in the neck that was present preoperatively. Four patients (4/30) required a planned combined technique for stone removal; stones related to the submandibular gland could be easily palpated in the floor of the mouth and could be removed through and intraoral incision. Retrieval of a stone in the parotid gland required an external approach through a standard parotidectomy incision.

Table 3  
Outcomes for stones (≥5 mm in diameter)

Gland	CT	Gross	Largest diameter (mm)	Length (along duct) (mm)	Width (mm)	Shape	Approach	Outcome
Parotid	+	–	7	7	5	Oval	Endoscopic	Success
Parotid	+	+	7	7	2	Oval-thin stone	Endoscopic	Success
SMG	+	–	6.4	6.4	5.5	Oval	Endoscopic	Success
SMG	–	+	6	6	3	Oval	Endoscopic	Success
SMG	+	+	5	5	4	Round	Endoscopic	Success
SMG	+	–	6.1	6.1	5.7	Round	Endoscopic	Failure
SMG	–	+	12	–	–	–	Endoscopic	Failure
SMG	+	+	9	9	3	Oval-thin stone	Endoscopic*	Success
SMG	+	–	8	8	8	Round	Combined	Success
SMG	+	+	12	–	–	–	Combined	Success
SMG	+	+	10	10	6	Round	Combined	Success
Parotid	+	+	5	5	2	Oval	Combined	Success

\* Patient was consented for combined approach.

The success rate for planned combined approach was a 100% with no incidence of major complications.

#### 4. Discussion

The incidence of salivary stones in the general population has been estimated to be 1.2% [3]. Sialolithiasis continues to be one of the leading causes of nonneoplastic disorders and unilateral diffuse swelling of the major salivary glands [1].

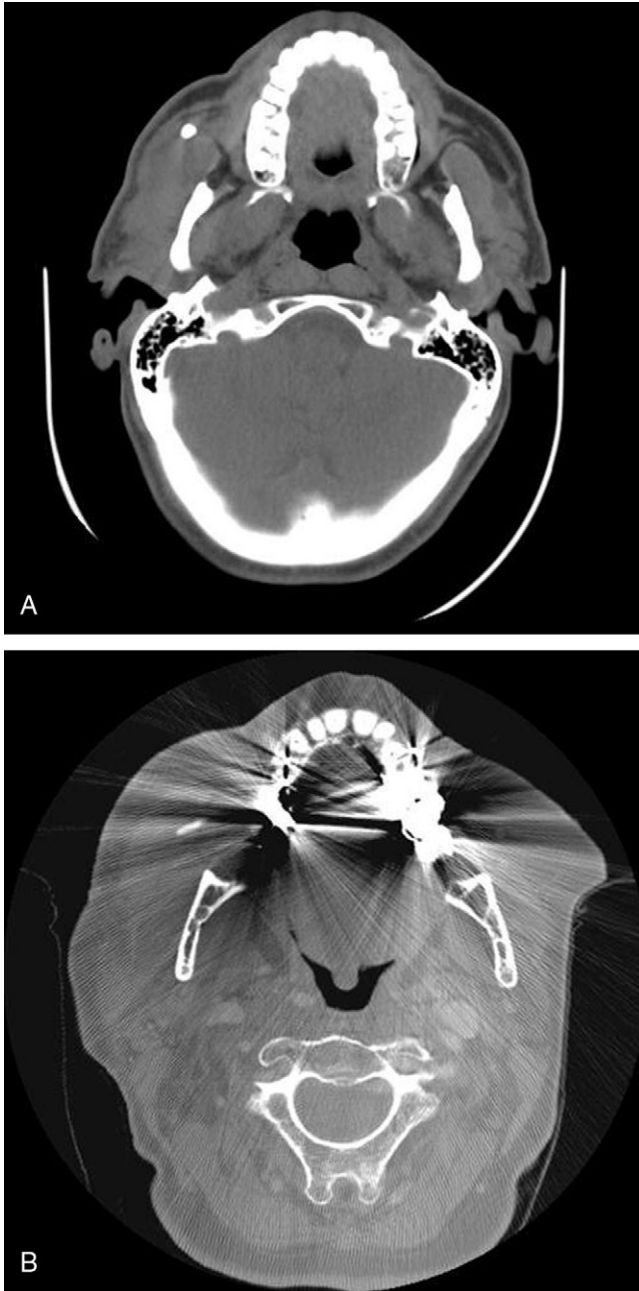


Fig. 1. A, Parotid stone measuring 7 × 5 mm—endoscopic removal not successful. B, Parotid stone measuring 7 × 2 mm—endoscopic removal successful.



Fig. 2. Submandibular stone measuring 9 × 3 mm—endoscopic removal successful.

Salivary gland stones may vary in size and shape. The size of the stone can vary from 2 to 2cm, with the mean size being 3.2 and 4.9 mm for parotid and submandibular stones, respectively [4,5]. In our series, the mean size of the stones ranged from 2 to 1.2 cm with an average of 4.5 and 4.4mm for submandibular and parotid stones, respectively. Salivary stones tend to grow at a rate of 1 mm/y [6]. Marchal [5] reported that 97% of stones smaller than 3 mm could be retrieved with the wire basket; however, success rates were dismal at 35% for larger stones. Marchal and Dulguerov [1] suggested an algorithm for stone removal, which is widely accepted, the recommendation being that stones less than 4 mm in their maximum diameter within the for submandibular gland and less than 3 mm within the parotid gland are amenable to endoscopic removal. Larger stones required prior fragmentation [1]. Nahlieli et al [3] recommended that intraductal extraction was possible for stones less than 5 mm in diameter. Although there may be differences in experiences regarding the optimal cutoff for when endoscopic extraction is considered feasible, there is a universal agreement that the largest diameter of the stone determines the approach for endoscopic removal of sialoliths. There is also a consensus that larger stones require an alternate approach which could be either prior fragmentation or a combined technique for removal.

In our series, we found endoscopic excision was successful in stones ranging from 2 to 9 mm and 2 to 7 mm for submandibular and parotid gland, respectively. Similarly, we had failures in stones ranging across these dimensions as well. What made endoscopic sialolithotomy successful in some larger stones (>5 mm) while not in others? Clearly, there are factors other than purely diameter of the stone that affect successful endoscopic sialolithotomy. From our observations, we suggest that large stones that were amenable to endoscopic removal with a wire basket had their largest dimension as measured on axial computed tomographic imaging, oriented along the length of the

salivary duct. Provided that the diameter of the stone in the plane perpendicular to the duct was not greater than recommended dimensions for successful stone removal (4 mm for submandibular and 3 mm for parotid cases), successful retrieval was possible (Fig. 1A and B). Consequently, larger stones amenable to endoscopic extraction tended to be longer and thinner or oval in shape (Fig. 2). There have been suggestions that that round stones are more amenable to endoscopic removal, as opposed to stones with irregular edges, which tend to get impacted in the wall of the duct. However, our study is the first observational study that shows a clear correlation between shape, size, orientation, and successful endoscopic stone removal. Another important intra-operative finding was that larger stones that were removed endoscopically were free-floating upon irrigation of the duct, as compared to more those which could not be removed endoscopically.

There are several other factors which can influence the retrieval of sialoliths, such as location of the stone and presence of ductal stenosis, active inflammation, or radioiodine-induced damage to the ducts of the salivary glands. However, until we better understand and characterize these variables, they will continue to pose a limitation to predicting successful stone removal. As a result, it may be prudent to preoperatively consent the patients and plan for alternative techniques of stone removal to improve success rates where endoscopic removal of stone is anticipated to be challenging.

For larger stones, several methods of fragmentation have been proposed such as external lithotripsy and intracorporeal laser fragmentation [7,8]. However, these newer therapeutic options have not been validated or Food and Drug Administration–approved for use in the United States. We have adopted the use of the combined minimally invasive approach for planned removal of larger stone considered not to be optimal for endoscopic extraction [2]. In our limited experience with 3 cases, we had excellent results with no complications. In our opinion, the advantage to planning a combined approach for larger stones is that the surgeon and patients are prepared for an alternative strategy for stone removal reducing uncertainty, improving success rates and potentially avoiding a second procedure.

There are several limitations of our study. The retrospective nature of the data, small sample size, and lack of extended follow-up limits our ability to make strong, powered recommendations based on our clinical observations. However, there is a clear association between stone diameter, orientation, and shape, which has relevance to clinical decision making regarding approach for endoscopic stone removal. Future studies and larger patient series will further validate our findings.

## 5. Conclusions

Preoperative evaluation of the orientation, shape, and dimensions of the sialolith can provide valuable predictive information regarding successful endoscopic stone removal. Salivary stones larger than 4 mm for submandibular cases and 3 mm for parotid cases may be amenable to endoscopic removal, provided their largest dimension is orientated favorably along the length of the duct.

## References

- [1] Marchal F, Dulguerov P. Sialolithiasis management: the state of the art. *Arch Otolaryngol Head Neck Surg* 2003;129:951-6.
- [2] Marchal F. A combined endoscopic and external approach for extraction of large stones with preservation of parotid and submandibular glands. *Laryngoscope* 2007;117:373-7.
- [3] Nahlieli O, Nakar LH, Nazarian Y, et al. Sialoendoscopy: a new approach to salivary gland obstructive pathology. *J Am Dent Assoc* 2006;137:1394-400.
- [4] Marchal F, Dulguerov P, Becker M, et al. Submandibular diagnostic and interventional sialendoscopy: new procedure for ductal disorders. *Ann Otol Rhinol Laryngol* 2002;111:27-35.
- [5] Marchal F, Dulguerov P, Becker M, et al. Specificity of parotid sialendoscopy. *Laryngoscope* 2001;111:264-71.
- [6] Raunch S, Gorlin RJ. Diseases of the salivary glands. In: Gorlin RJ, editor. *Thomas' Oral Pathology*. St.Louis: M0:CV Mosby; 1970. p. 997-1003.
- [7] Katz P. New techniques for the treatment of salivary lithiasis: sialoendoscopy and extracorporeal lithotripsy: 1773 cases. *Ann Otolaryngol Chir Cervicofac* 2004;121:123-32.
- [8] Raif J, Vardi M, Nahlieli O, et al. An Er:YAG laser endoscopic fiber delivery system for lithotripsy of salivary stones. *Lasers Surg Med* 2006; 38:580-7.